



Cystic Encephalomalacia and Infantile Spasm as a Complication of Transient and Mild Hyperinsulinemic Hypoglycemia

Geçici ve Hafif Hiperinsülinemik Hipogliseminin Komplikasyonu Olarak Kistik Ensefalomalazi ve Infantil Spazm

Ahmet Anık¹, Ayşe Anık², Tolga Ünüvar¹, Ayşe Fahriye Tosun³, Şiar Dursun³, Abdullah Barış Akcan², Yasemin Durum⁴, Münevver Kaynak Türkmen²

¹Adnan Menderes University Faculty of Medicine, Department of Pediatric Endocrinology, Aydın, Turkey

²Adnan Menderes University Faculty of Medicine, Department of Neonatology, Aydın, Turkey

³Adnan Menderes University Faculty of Medicine, Department of Pediatric Neurology, Aydın, Turkey

⁴Adnan Menderes University Faculty of Medicine, Department of Radiology, Aydın, Turkey

ABSTRACT

Although it is known that hypoglycemia could cause severe negative effects on brain development and also infantile spasm, it has not been reported that transient hyperinsulinemic hypoglycemia, which spontaneously improves over a short time, may cause infantile spasms. Infantile spasm is a disorder of early childhood typically seen in the first year of life, characterized by the occurrence of sudden, brief, generally bilateral and symmetric motor spasms of the muscles of the trunk, neck and limbs. Infantile spasms are classified as idiopathic or symptomatic. The most common form symptomatic infantile spasms is due to prenatal, perinatal or postnatal insults. A 3140 g, full-term baby was admitted with poor sucking and feeding difficulty on the postnatal second day. The patient was followed-up with the diagnosis of hyperinsulinemic hypoglycemia and intravenous glucose infusion (15 mg/kg/min) was administered, but due to the persistence of hypoglycemia, diazoxide treatment was initiated. Hypoglycemia was not observed under diazoxide treatment and the drug was gradually decreased; treatment was terminated on the 21st day. The patient was continuously normoglycemic during follow-up and admitted with flexor spasms on the 45th day. A modified hypsarrhythmia pattern was detected in the electroencephalography. On cranial magnetic resonance imaging, diffuse cystic encephalomalacia areas were observed in the temporoparietal white and gray matter. The convulsions were not completely controlled with adrenocorticotrophic hormone and vigabatrin treatments. Topiramate and valproate were administered, by which convulsions were partially controlled.

Keywords: Infantile spasm, transient hypoglycemia, hyperinsulinemia

ÖZ

Hipogliseminin beyin gelişimi üzerine olan olumsuz etkileri ve infantil spazma neden olabileceği iyi bilinmekle birlikte, kısa sürede ve spontan olarak iyileşen hiperinsülinemik hipogliseminin infantil spazma neden olabileceği bildirilmemiştir. Infantil spazm genellikle yaşamın ilk yılında ortaya çıkan, gövde, boyun ve bacak kaslarının ani, kısa süreli ve genellikle bilateral simetrik motor spazmları olarak tanımlanır. En sık görülen formu olan semptomatik infantil spazm prenatal, perinatal ve postnatal olaylara bağlı ortaya çıkar. Zamanında 3140 gram olarak doğan bebek postnatal ikinci gününde zayıf emme ve beslenme güçlüğü yakınmaları ile getirildi. Hiperinsülinemik hipoglisemi tanısı konan ve intravenöz glukoz infüzyonuna (15 mg/kg/dk) rağmen hipoglisemisi devam eden olguya diazoksit başlandı. Bu tedavi ile hipoglisemisi gözlenmeyen olgunun diazoksit dozu kademeli olarak azaltılarak 21. günde kesildi. İzlemede sürekli normoglisemik olan bebek 45. günde fleksör spazmlar nedeni ile başvurdu. Elektroensefalografide modifiye hipsartimi paterni saptandı. Kranial manyetik rezonans görüntülemeye temporoparietal beyaz ve gri cevherde kistik ensefalomalazik alanlar gözlemlendi. Adrenokortikotropik hormon ve vigabatrin tedavileri ile nöbetleri kontrol altına alınamayan olguda topiramate ve valproat tedavilerinden kısmi fayda görüldü.

Anahtar Kelimeler: Infantil spazm, geçici hipoglisemi, hiperinsülinemi

Address for Correspondence/Yazışma Adresi

Ahmet Anık, MD, Adnan Menderes University Faculty of Medicine, Department of Pediatric Endocrinology, Aydın, Turkey
Phone: +90 532 568 43 40 E-mail: ahmet.anik@yahoo.com

Received/Geliş tarihi: 17.09.2015 Accepted/Kabul tarihi: 07.04.2016

Introduction

Hyperinsulinemic hypoglycemia (HH) is the most common cause of persistent hypoglycemia in infants posing significant risk of permanent brain damage (1). Hyperinsulinism inhibits glycogenolysis, gluconeogenesis, lipolysis, ketogenesis and leads to a lack of alternative fuels available for brain function (2). The brain is quite sensitive to the negative effects of hypoglycemia, and as such, cerebral palsy and epilepsy due to hypoglycemia are observed (3).

Infantile spasms are a rare form of epilepsy that usually begins in children younger than one year, characterized by a sudden, generally bilateral and symmetric contractions of the muscles of the neck, trunk, and extremities (4). The onset is typically in infancy, and associated interictal electroencephalograms (EEGs) show a chaotic high voltage pattern called hypsarrhythmia, although this can vary (5). Approximately 15% of the cases are idiopathic, and the rest are symptomatic. The symptomatic cases are associated with several prenatal, perinatal, and postnatal factors (including hypoglycemia), tuberous sclerosis, structural brain lesions, chromosomal abnormalities, or single gene defects (2).

Although it is known that hypoglycemic brain injury could cause infantile spasms, the mechanism is not precisely known. A total of six patients with HH-related infantile spasms were reported in two different articles in the literature (2,6). In these patients, the common characteristic was the necessity of medical treatment in HH and the development of infantile spasms following a certain latent period. The present case report presents an infant who was diagnosed with HH in the neonatal period and developed infantile spasms and cystic encephalomalacia, although spontaneous remission of HH developed in a short period.

Case Report

A 3140 g, male, full-term infant, who was born through normal spontaneous vaginal delivery after an uncomplicated pregnancy and who had appearance, pulse, grimace, activity,

respiration scores of 8 and 9 at the first and fifth minutes, respectively, was admitted with poor sucking and feeding problems on the postnatal second day. The patient was hospitalized, as the venous blood glucose level at admission was 29 mg/dL. There was no consanguinity between the mother and the father. On physical examination, the body weight was 3185 g (25-50p), height was 85 cm (25-50p), and head circumference was 34 cm (50p). The systemic examination was normal. Intravenous glucose was administered as bolus to treat hypoglycemia and there was a requirement of glucose infusion at 15 mg/kg/minimum during follow-up. Phenobarbital was initiated to treat tonic-clonic convulsions. The patient's serum insulin level was 13.7 g/dL and urine was negative for ketone during hypoglycemia. As the blood glucose level increased with glucagon treatment, the case was diagnosed with HH. Serum growth hormone, cortisol and plasma ammonia levels were normal. Diazoxide treatment was initiated at 15 mg/kg/day, and as hypoglycemia improved after the postnatal fifth day, intravenous glucose infusion was terminated, and total enteral feeding was started. The EEG during this period was within normal limits according to the age. As the venous glucose levels were high, diazoxide treatment was terminated on the postnatal 21st day and the patient was discharged on phenobarbital treatment due to the absence of hypoglycemia in the follow-up.

At 2.5 months of age the patient developed infantile spasms with 2-3 clusters per day which were not associated with hypoglycemia (Figure 1). Physical examination revealed microcephaly (head circumference 35 cm) and the EEG was abnormal with epileptiform discharges consistent with hypersyncron/modified hypsarrhythmia (Figure 2). The cranial magnetic resonance imaging (MRI) revealed large cystic encephalomalacia areas in which there was thinning and hyperintensity in the adjacent cortex in the periorlandic area in both the parieto-occipital and frontal lobes, primarily concentrated in the parieto-occipital area. A diffuse intensity increase was observed in the subcortical and deep white matter adjacent to this area in T2A images (Figure 3). No diffusion restriction was observed in the diffusion

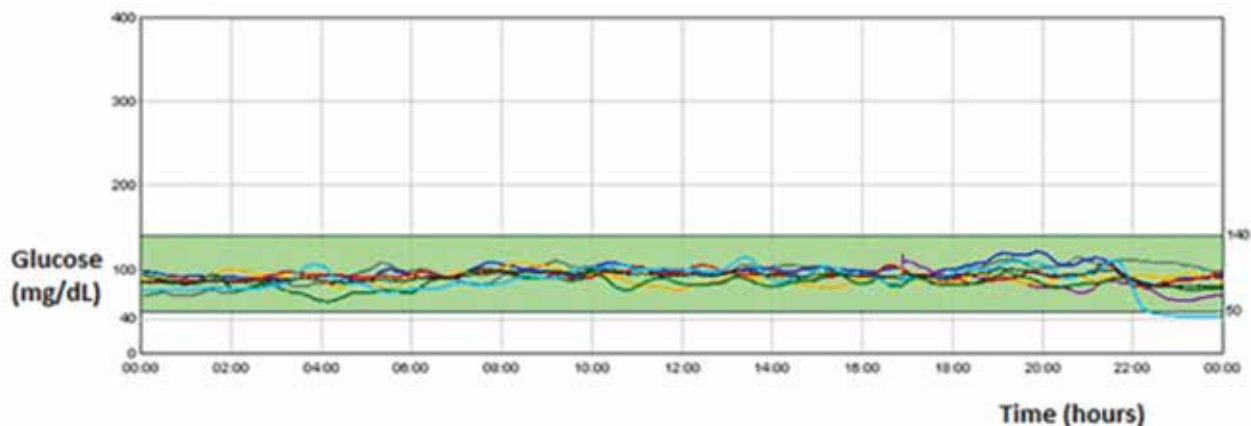


Figure 1. Continuous glucose monitoring system of the patient showed normoglycemia (each curve color represents a separate day)

weighted images. The findings were thought to be related to hypoglycemic brain injury. Serum uric acid level, plasma amino acids, carnitine-acyl carnitine profile, ammonium level (91 ug/dL), cerebrospinal fluid analysis, and urine organic acid levels were normal. The infantile spasms did not respond to vigabatrin or adrenocorticotrophic hormone therapy and the patient was commenced on valproate and topiramate, which resulted in a slight reduction in seizures.

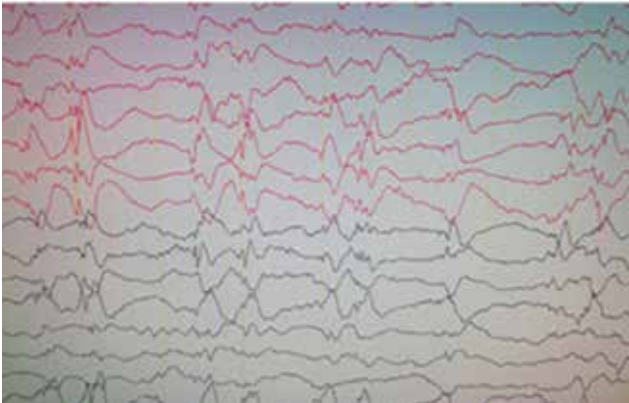


Figure 2. An abnormal electroencephalogram with hypersynchronous modified hypsarrhythmia

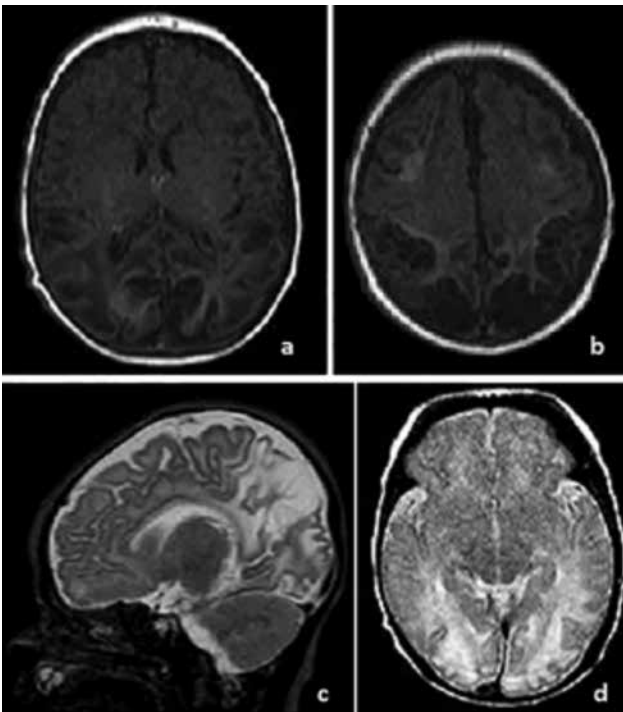


Figure 3. Cranial magnetic resonance imaging findings of a 24-day-old newborn. a-b) In the axial T1A images, there is increased intensity in the cortical regions and deep sulcus, especially in the bilateral parieto-occipital area, which is accompanied by tissue loss in the borders of the bilateral frontal lobes
c-d) In the sagittal and axial T2A images, there is cystic encephalomalacic changes in the bilateral parieto-occipital region and diffuse increase in the intensity in white matter

Discussion

Hypoglycemia is an important cause of brain damage that particularly affects the neonate and infant (7). In 1994, Spar et al. (8) first reported prominent thinning in the cerebral cortex and prominent involvement in the parieto-occipital lobes in isolated neonatal hypoglycemia. Brain damage usually involves the white matter of the posterior regions, but the basal ganglia and cortex may also be affected (9,10). It has been reported that the posterior white matter is primarily affected in hypoglycemia developing within the first six months of life, whereas the basal ganglion and cortex are affected more in hypoglycemia developing after six months (7). In cranial MRI, hyperintense lesions, gliosis, cortical atrophy, and cystic encephalomalacia could be observed in the white matter in T2/fluid attenuation inversion recovery sequence (11,12). In the present case, the presence of posterior white matter involvement and cystic encephalomalacia were found to be consistent with the literature.

The incidence of epilepsy following symptomatic neonatal hypoglycemia is greater than 50% and the most frequent type of epilepsy is focal occipital epilepsy (13-15). Hypoglycemia is a known cause of infantile spasms, but the mechanism of how hypoglycemic brain injury causes infantile spasms is unclear. HH is a form of hypoglycemia that is associated with a high risk of developmental delay, mental retardation, and epilepsy (3). The unique biochemical profile (with insulin-inhibiting glycogenolysis, gluconeogenesis, lipolysis, and ketogenesis) observed in patients with HH renders the brain more susceptible to injury in comparison with other hypoglycemic states (2). The relationship of epilepsy and HH was defined in hyperinsulinemia/hyperammonemia syndrome, which develops as a result of a *GLUD1* gene mutation and is typically characterized by generalized tonic-clonic convulsions in these patients (16). In the literature, there are only a few cases of normo-ammoniemic HH-related infantile spasms and West syndrome. Camurdan et al. (6) reported the development of West syndrome in a 6-month-old infant who was diagnosed with HH and became normoglycemic following diazoxide and nifedipine treatments. In the study of Kumaran et al. (2) in which they examined the development of infantile spasms in five cases with HH, they reported that all of the cases had hypoglycemia during the neonatal period and were diagnosed with HH. They stated that three patients were treated with diazoxide and two patients were treated with pancreatectomy, and infantile spasms developed 3-9 months later. Similar to the present case, the development of infantile spasms after a certain latent period was found to be consistent with the literature.

Conclusion

Findings from our case and other series highlight that infantile spasms may be the presenting seizure in children with a history of neonatal HH. In addition, although hypoglycemia

was short lasting and not resistant, the development of infantile spasms during the follow-up period demonstrated that cases with HH should be followed-up in this respect. Our clinical observations suggest that significant brain damage that results in infantile spasms and poor neurodevelopmental outcome can occur despite the early diagnosis of HH.

The present case report emphasized that even HH is short-term and transient; (i) it could cause cerebral damage, (ii) it could present as infantile spasms in the late period, and therefore, (iii) long-term follow-up is important for these patients.

Ethics

Informed Consent: Obtained.

Peer-review: Externally peer-reviewed.

Authorship Contributions

Surgical and Medical Practices: Ayşe Anik, Şiar Dursun, Concept: Ahmet Anik, Tolga Ünüvar, Design: Ahmet Anik, Data Collection or Processing: Ayşe Anik, Analysis or Interpretation: Yasemin Durum, Münevver Kaynak Türkmen, Ayşe Fahriye Tosun, Literature Search: Abdullah Barış Akcan, Writing: Ahmet Anik.

Conflict of Interest: No conflict of interest was declared by the authors.

Financial Disclosure: The authors declared that this study has received no financial support.

References

1. Mohamed Z, Arya VB, Hussain K. Hyperinsulinaemic hypoglycaemia: genetic mechanisms, diagnosis and management. *J Clin Pediatr Endocrinol* 2012;4:169-81.
2. Kumaran A, Kar S, Kapoor RR, Hussain K. The clinical problem of hyperinsulinemic hypoglycemia and resultant infantile spasms. *Pediatrics* 2010;126:1231-6.
3. Menni F, de Lonlay P, Sevin C, et al. Neurologic outcomes of 90 neonates and infants with persistent hyperinsulinemic hypoglycemia. *Pediatrics* 2001;107:476-9.
4. Pavone P, Striano P, Falsaperla R, Pavone L, Ruggieri M. Infantile spasms syndrome, West syndrome and related phenotypes: what we know in 2013. *Brain Dev* 2014;36:739-51.
5. Caraballo RH, Ruggieri V, Gonzalez G. Infantile spasms without hypsarrhythmia: a study of 16 cases. *Seizure* 2011;20:197-202.
6. Camurdan MO, Cinaz P, Serdaroglu A, Bideci A, Demirel F. Persistent hyperinsulinemic hypoglycemia presenting with a rare complication: West syndrome. *J Pediatr Endocrinol Metab* 2004;17:1465-8.
7. Gataullina S, De Lonlay P, Dellatolas G, et al. Topography of brain damage in metabolic hypoglycaemia is determined by age at which hypoglycaemia occurred. *Dev Med Child Neurol* 2013;55:162-6.
8. Spar JA, Lewine JD, Orrison WW, Jr. Neonatal hypoglycemia: CT and MR findings. *AJNR Am J Neuroradiol* 1994;15:1477-8.
9. Barkovich AJ, Ali FA, Rowley HA, Bass N. Imaging patterns of neonatal hypoglycemia. *AJNR Am J Neuroradiol* 1998;19:523-8.
10. Ma JH, Kim YJ, Yoo WJ, et al. MR imaging of hypoglycemic encephalopathy: lesion distribution and prognosis prediction by diffusion-weighted imaging. *Neuroradiology* 2009;51:641-9.
11. Caksen H, Güven AS, Yilmaz C, et al. Clinical outcome and magnetic resonance imaging findings in infants with hypoglycemia. *J Child Neurol* 2011;26:25-30.
12. Fong CY, Harvey AS. Variable outcome for epilepsy after neonatal hypoglycaemia. *Dev Med Child Neurol* 2014;56:1093-9.
13. Yalnizoglu D, Haliloglu G, Turanli G, Cila A, Topcu M. Neurologic outcome in patients with MRI pattern of damage typical for neonatal hypoglycemia. *Brain Dev* 2007;29:285-92.
14. Murakami Y, Yamashita Y, Matsuishi T, Utsunomiya H, Okudera T, Hashimoto T. Cranial MRI of neurologically impaired children suffering from neonatal hypoglycaemia. *Pediatr Radiol* 1999;29:23-7.
15. Alkalay AL, Flores-Sarnat L, Sarnat HB, Moser FG, Simmons CF. Brain imaging findings in neonatal hypoglycemia: case report and review of 23 cases. *Clin Pediatr (Phila)* 2005;44:783-90.
16. Bahi-Buisson N, Roze E, Dionisi C, et al. Neurological aspects of hyperinsulinism-hyperammonaemia syndrome. *Dev Med Child Neurol* 2008;50:945-9.