



Cerebral Involvement of Hemophagocytic Lymphohistiocytosis in Griscelli Syndrome

© Ersin Töret¹, © Yılmaz Ay¹, © Serap Aksoylar², © Tuba Hilkey Karapınar¹, © Yeşim Oymak¹

¹University of Health Sciences, Dr. Behçet Uz Children's Training and Research Hospital, Clinic of Pediatric Hematology Oncology, İzmir, Turkey

²Ege University Faculty of Medicine, Pediatric Kit Unit, Department of Pediatric Hematology Oncology, İzmir, Turkey

ABSTRACT

Type II Griscelli Syndrome (GS) is caused by a mutation in the *RAB27A* gene and usually manifests with silvery-gray hair, immune deficiency and the development of hemophagocytic lymphohistiocytosis (HLH). A hematopoietic stem cell transplantation is the curative treatment for HLH and reduced-intensity conditioning prevents the morbidity/mortality in the transplantation related to myeloablative conditioning. We report on a 21-month old boy with cerebral involvement of HLH related to GS.

Keywords: Griscelli Syndrome, hemophagocytic lymphohistiocytosis, hematopoietic stem cell transplantation

Introduction

Griscelli Syndrome (GS), which is a rare autosomal recessive disease which is characterized by cellular immune deficiency and partial albinism, was first described in 1978. Clinical manifestations of GS are silvery-gray hair, abnormal regulation of immunity and different degrees of cyto- and pancytopenia (1). GS is classified into three different subtypes regarding its clinical and molecular features. Type II GS is caused by a mutation in the *RAB27A* gene and usually manifests with silvery-gray hair, recurrent infections due to immune deficiency and development of hemophagocytic lymphohistiocytosis (HLH) (1,2). HLH related to uncontrolled hemophagocytosis and fever, severe cytopenia, hepatosplenomegaly, skin rash, jaundice, hyponatremia, hypoalbuminemia and hyperferritinemia are well-known clinical manifestations of the disease. Also, the central nervous system (CNS) is involved in patients

with HLH with an incidence of more than 33% to 75% (3). Hematopoietic stem cell transplantation (HSCT) is the curative treatment for primary HLH like GS, with or without CNS involvement. Recently, reduced-intensity conditioning (RIC), which possesses risks like primary graft failure and the loss of chimerism, has been reported to reduce the high mortality in transplantation compared to the myeloablative conditioning regimens (4). In this case report, we evaluated a 21-month old boy with cerebellar involvement of HLH related to GS. He was treated with allogeneic HSCT, RIC and donor lymphocyte infusion (DLI) for a mixed chimera.

Case Report

A 21-month old boy was admitted to the emergency unit for 3 days due to fever. A viral upper respiratory tract system infection was suspected. However, physical examination revealed silvery-gray hair, eyebrows and

Address for Correspondence

Ersin Töret MD, University of Health Sciences, Dr. Behçet Uz Children's Training and Research Hospital, Clinic of Pediatric Hematology Oncology, İzmir, Turkey
Phone: +90 505 799 42 34 E-mail: drersintoret@hotmail.com ORCID: orcid.org/0000-0002-6379-8326

Received: 05.09.2018 Accepted: 28.11.2018

©Copyright 2019 by Ege University Faculty of Medicine, Department of Pediatrics and Ege Children's Foundation
The Journal of Pediatric Research, published by Galenos Publishing House.

eyelashes. At first sight, his silvery-gray hair attracted our attention and a microscopic evaluation of the hair shaft showed typical large irregular melanin granules instead of small homogeneous pigment granules as in normal hair. His parents were consanguineous and there was no evidence of similar conditions in his family history. The family was informed about GS and a blood sample was sent to a laboratory for the identification of a mutation of the *RAB27A* gene. The immunoglobulin (Ig) levels were checked and the IgG level was 452 mg/dL (normal range: 300-1240 mg/dL), the IgM level was 67 mg/dL (normal range: 45-200) and the IgA level was 28 mg/dL (normal range: 18-150 mg/dL). Lymphocyte profiling was normal according to a pediatric immunology consultant. Approximately one month later, the patient was admitted again to the clinic for 5 days suffering from fever. Physical examination showed pallor, tachycardia due to the fever and hepatosplenomegaly (the liver was palpable 2 cm below the right costal margin and the spleen was palpable 3 cm below the left costal margin). Laboratory data revealed bicytopenia (anemia and neutropenia) and hyperferritinemia. Hemophagocytosis was detected in the bone marrow smear. In light of all these findings, the patient was diagnosed with HLH. As a mutation in the *RAB27A* gene was detected [homozygous mutation for p.L26P (c.77T>C)], the final diagnosis of the patient was confirmed as GS Type II. In line with the Treatment Protocol of HLH 2004, a combination therapy with dexamethasone, cyclosporine A (CsA) and etoposide was administered. Donor screening was concomitantly started to find a matched donor for HSCT. Intrathecal treatment was not

considered as there were no neurologic findings in the physical examination. No pleocytosis or no abnormal protein level in cerebrospinal fluid (CSF) were observed. After the patient entered remission at the end of the induction therapy, maintenance therapy was initiated. The patient developed irritability, hypotonia and fever at the 16th month of treatment, while he was being treated with CsA and waiting for a matched unrelated donor (MUD). CSF examination revealed abnormal findings like pleocytosis and elevated protein. The cranial magnetic resonance imagination (MRI) showed cerebral involvement of HLH. The MRI demonstrated periventricular localized profound hyperintense nodules and subcortical diffuse hyperintense areas in the temporal and frontal lobes (Figure 1). Treatment was restarted according to the first-line therapy principles of the HLH-2004 protocol. The patient underwent allogeneic HSCT obtained from a MUD at the 9th month of the reactivation of HLH, while the disease was not in the active phase, and was successfully engrafted after 22 days. The RIC regimen consisted of 0.2 mg/kg alemtuzumab for 5 consecutive days (days -12 to -8), fludarabine 30 mg/m² for 5 consecutive days (days -8 to -4), melphalan 140 mg/m² for 1 day (day -3). CsA and methylprednisolone 1 mg/kg/day were administered for prophylaxis against Graft versus Host Disease. At the eighth month, due to the presence of mixed chimerism (30% donor chimerism), DLI was performed to prevent graft failure while the patient was in remission. He has been in remission for over 12 months after HSCT. At the ninth month, cranial MRI was almost normal without any finding of CNS involvement for 21 months with mixed

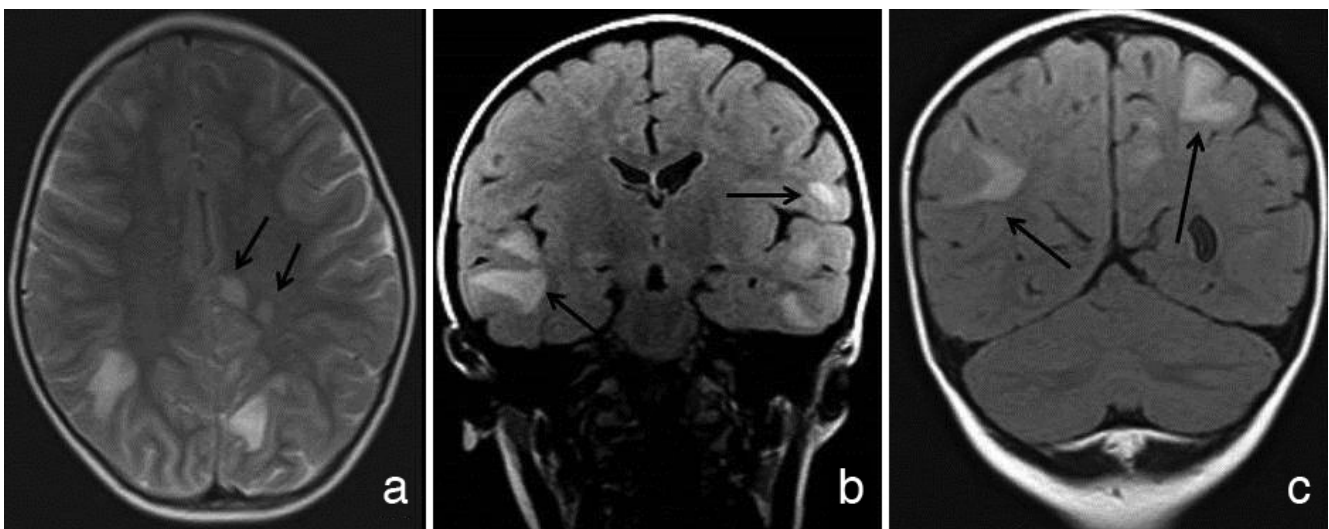


Figure 1. a) T2-weighted axial image shows periventricular profound-localized hyperintense nodules, (b,c) coronal FLAIR images demonstrate subcortical diffuse hyperintense areas in bilateral temporal and frontal lobes

chimerism. There was evident regression in hyperintense nodules and complete disappearance of subcortical diffuse hyperintense areas in MRI. The general neurological and mental development was summarized as his speech and motor functions were delayed but his emotional and cognitive abilities were similar to his peers. Informed consent was received from family.

Discussion

GS is a rare hereditary disease although the frequency is relatively higher in some ethnic groups with a high incidence of consanguineous marriages. HLH is a troublesome condition that involves the *RAB27A* gene mutation associated with the Type II GS. CNS involvement of HLH is a variable condition that can be detected at any time during the follow-up of the disease and shows heterogeneous characteristics regarding the clinical presentation, ranging from irritability, headache, convulsions, ataxia, central nerve palsies and from stupor to coma. Involvement of CNS can be detected via CSF examination and neuroradiological examination. Abnormal findings of CSF are elevated leukocyte cell count (pleocytosis) and/or protein levels. There is a correlation between the neuroradiological findings and histopathological stages of CNS involvement of HLH as previously reported. Considering the stages; stage 1 is defined as a mild and common presentation with leptomeningeal inflammatory infiltrates, stage 2 involves perivascular infiltration and stage 3 is characterized by massive tissue infiltration-necrosis and vascular destruction. The neuroimaging of the CNS involvement in HLH includes focal or diffuse abnormalities like periventricular hyperintensity in T2 images, expanded perivascular areas, white-gray matter changes and parenchymal atrophy without any specific features (5,6). In our case, we observed periventricular hyperintense nodules and subcortical diffuse hyperintensity. Although these findings are not specific for CNS involvement in HLH, certain concomitant findings supported the diagnosis.

HSCT is a unique way to cure patients with primary HLH like GS Type II. In the literature, there are few cohort studies and case reports which described allogeneic HSCT for GS Type II (7-9). Pachlopnik Schmid et al. (9) reported that 7 of 10 patients with HLH had CNS involvement before HSCT and 5 of them had irreversibly suffered from a neurological deficit. The overall survival rate of these 10 patients was 70%. In another study, 7 of 11 patients with HLH had CNS involvement before HSCT. The overall survival of these patients with GS Type II who underwent

allogeneic HSCT was more than 75%. Unfortunately, 4 of the 7 patients with CNS involvement had a neurological deficit such as developmental delay or speech abnormality (10). As Al-Ahmari et al. (10) emphasized, HSCT could be a good choice for the treatment of the disease and to prevent neurological complications when performed before the emergence of HLH. In our case, abnormal findings in CSF and neurological examination have resolved after HSCT.

Conclusion

Only a few cases with cerebral involvement of HLH related to GS Type II who were treated with allogeneic HSCT have been published. In our case, HSCT was performed with non-myeloablative conditioning. Eighteen months after HSCT was performed, the patient was in remission and had no neurological findings in spite of mixed chimerism. RIC prevented the morbidity/mortality in the transplantation related to the myeloablative conditioning and mixed chimerism would be sufficient for the prevention of the disease activation. DLI is an effective method for preventing graft failure.

Ethics

Informed Consent: Informed consent was received from family.

Peer-review: Externally peer-reviewed.

Authotship Contributions

Surgical and Medical Practices: E.T., Y.A., S.A., T.H.K., Y.O., Design: E.T., Y.A., Data collection or Processing: E.T., Y.A., Analyses or Interpretation: Y.A., S.A., Literature Search: E.T., Y.A., Writing: E.T.

Conflict of Interest: No conflict of interest was declared by the authors.

Financial Disclosure: The authors declared that this study received no financial support

References

1. Panigrahi I, Suthar R, Rawat A, Behera B. Seizure as the presenting manifestation in Griscelli syndrome Type 2. *Pediatr Neurol* 2015;52:535-8.
2. Griscelli C, Prunieras M. Pigment dilution and immunodeficiency: A new syndrome. *Int J Dermatol* 1978;17:788-91.
3. Dotta L, Parolini S, Prandini A, et al. Clinical, laboratory and molecular signs of immunodeficiency in patients with partial oculo-cutaneous albinism. *Orphanet J Rare Dis* 2013;8:168.
4. Rosado FG, Kim AS. Hemophagocytic lymphohistiocytosis: An update on diagnosis and pathogenesis. *Am J Clin Pathol* 2013;139:713-27.

5. Henter JI, Horne A, Aricò M, et al. HLH-2004: Diagnostic and therapeutic guidelines for hemophagocytic lymphohistiocytosis. *Pediatr Blood Cancer* 2007;48:124-31.
6. Fitzgerald NE, MacClain KL. Imaging characteristics of hemophagocytic lymphohistiocytosis. *Pediatr Radiol* 2003;33:392-401.
7. Horne A, Trottestam H, Aricò M, et al. Frequency and spectrum of central nervous system involvement in 193 children with haemophagocytic lymphohistiocytosis. *Br J Haematol* 2008;140:327-35.
8. Aricò M, Zecca M, Santoro N, et al. Successful treatment of Griscelli syndrome with unrelated donor allogeneic hematopoietic stem cell transplantation. *Bone Marrow Transplant* 2002;29:995-8.
9. Pachlopnik Schmid J, Moshous D, Boddaert N, et al. Hematopoietic stem cell transplantation in Griscelli syndrome Type 2: A single-center report on 10 patients. *Blood* 2009;114:211-8.
10. Al-Ahmari A, Al-Chonaium A, Al-Mansoori M, et al. Hematopoietic SCT in children with Griscelli syndrome: A single-center experience. *Bone Marrow Transplant* 2010;45:1294-9.