



The Role of Late Dimercaptosuccinic Acid (DMSA) Scan and Renal Ultrasonography for Vesicoureteral Reflux in Older Children

✉ Nuran Çetin¹, ✉ Aslı Kavaz Tufan¹, ✉ İlknur Ak Sivrikoz², ✉ Nevbahar Akçar³

¹Eskişehir Osmangazi University Faculty of Medicine, Department of Pediatric Nephrology, Eskişehir, Turkey

²Eskişehir Osmangazi University Faculty of Medicine, Department of Nuclear Medicine, Eskişehir, Turkey

³Eskişehir Osmangazi University Faculty of Medicine, Department of Radiology, Eskişehir, Turkey

ABSTRACT

Aim: Vesicoureteral reflux (VUR) is an important risk factor for urinary tract infection (UTI). We aimed to investigate the relationships between VUR and ultrasound with late dimercaptosuccinic acid (DMSA) scan findings in children aged older than two years who had their first febrile UTI (FUTI).

Materials and Methods: Data from those patients with their first FUTI were retrospectively analyzed. A late DMSA scan was performed at least 6 months after an acute FUTI. The late DMSA scans were graded as mild (focal defect in uptake), moderate (uptake of renal radionuclide from 20 to 40%), and severe (shrunken kidney with uptake less than 20%). Micturating cystourethrography was performed at 3 to 6 weeks after the FUTI.

Results: The records of 220 patients (61 mild VUR, 60 severe VUR, 99 without VUR) were reviewed. An abnormal US was more common in those patients with VUR than those without VUR ($p=0.009$). Abnormal US had a sensitivity of 79.34% for VUR and 81.67% for severe VUR. The negative predictive value of renal US for severe VUR was 91.13%. The frequency of renal scarring was higher in those patients with VUR than for those without VUR (102/44, $p=0.001$). A logistic regression analysis showed significant associations between abnormal US and VUR or severe VUR ($p=0.019$ and $p=0.011$, respectively). Renal scarring had a sensitivity of 84.3% for VUR, and 91.67% for severe VUR.

Conclusion: Late DMSA scan findings can predict the presence and grade of VUR in older children who have their first FUTI. Normal renal US can predict the absence of severe VUR.

Keywords: Febrile urinary tract infection, late DMSA scan, older children, vesicoureteral reflux

Introduction

Urinary tract infections (UTI) are among the most common infections in childhood (1). The most common abnormality in children with UTI is vesicoureteral reflux (VUR). Children with VUR are at an increased risk of chronic kidney disease; therefore, it is important to determine the

presence and grade of VUR in children with febrile UTI (FUTI) (2).

Diagnostic radiological studies in children with FUTI are controversial. The National Institute for Clinical Excellence guideline does not recommend micturating cystourethrography (MCUG) after a child's first UTI (3). In recent years, the emphasis has been on identifying

Address for Correspondence

Nuran Çetin, Eskişehir Osmangazi University Faculty of Medicine, Department of Pediatric Nephrology, Eskişehir, Turkey
Phone: +90 533 622 75 36 E-mail: nurancetin17@hotmail.com ORCID: orcid.org/0000-0001-5763-9815

Received: 25.10.2020 Accepted: 28.01.2021

©Copyright 2021 by Ege University Faculty of Medicine, Department of Pediatrics and Ege Children's Foundation
The Journal of Pediatric Research, published by Galenos Publishing House.

patients who are at risk of recurrence of UTI and permanent renal damage rather than detecting VUR. This “top-down” approach implies that VUR has clinical significance only if it causes renal damage. A technetium 99 m-labeled dimercaptosuccinic acid (DMSA) scan is recommended to evaluate permanent renal damage (4).

In this study, we aimed to investigate the relationship between the presence of VUR and renal ultrasonography (US) with late DMSA scan findings in children older than two years who had their first FUTI.

Materials and Methods

The protocol for the present study was reviewed and approved by the Institutional Review Board of Eskişehir Osmangazi University Faculty of Medicine (approval number: 25403353-050.99-E.110593). In this retrospective study, the data of those patients with a first diagnosis of FUTI who were followed up in our Pediatric Nephrology Clinic between May 2015 and March 2019 were reviewed. Children with congenital anomalies of the kidney or urinary tract other than VUR, a history of FUTI and/or VUR diagnosis before the study and missing data and/or a follow-up period <2 years were excluded from the study. The patients with findings supporting congenital renal dysplasia, such as loss of corticomedullary differentiation and renal hyperechogenicity on US, and with unscarred kidneys with a differential function <45% were not included.

Urine samples for culture were obtained from midstream urine. All of the patients underwent genital hygiene with soap and water in the laboratory before providing a urine sample. The diagnosis of FUTI was made on the basis of the presence of fever >38 °C with at least 100,000 colony-forming units/mL of a uropathogen cultured from the urine specimen and pyuria (leucocyte counts ≥ 5 /high-power field).

In our Pediatric Nephrology Department, all patients underwent a renal US within two weeks of their first FUTI. The DMSA scan was performed at least six months after the diagnosis of FUTI in all patients. MCUG was performed on those patients with serious illness, septicemia, poor urine flow, raised creatinine, failure to respond to treatment with suitable antibiotics within 48 hours or infection with non-*E. coli* organisms, hydronephrosis, and/or other findings suggestive of VUR on ultrasound. Only those patients with complete radiological examinations were included in this study.

Hydronephrosis was defined using the Society for Fetal Urology’s grading system (5). Abnormal US was defined

by hydronephrosis, hydroureter (≥ 7 mm), parenchymal thinning, and dilatation of calyces.

Renal scarring was defined as a reduced or absent radionuclide uptake, a wedge-shaped defect, or the thinning or flattening of the renal outline. Reduced differential function (RDF) was defined as <45%. A kidney uptake of 45%-55% of the total renal activity was considered to be normal. The findings on DMSA scan were graded as mild (focal defect in uptake), moderate (uptake of renal radionuclide from 20%-40%), and severe (shrunken kidney with uptake less than 20%) (6). The DMSA scans were all evaluated by the same nuclear medicine specialist.

MCUG was performed at three to six weeks after the diagnosis of FUTI. VUR was graded according to the grading system of the International Reflux Study Committee. Grades 1-2 VUR were defined as mild VUR, while grades 3-5 VUR were defined as severe VUR. The pediatric radiologist and nuclear medicine specialist were unaware of the patients’ clinical and laboratory findings.

Statistical Analysis

Statistical analyses were performed using SPSS version 11.0 (SPSS Inc, Chicago, IL). Values are expressed as a mean and standard deviation for continuous variables and as an interquartile range for qualitative variables. Qualitative variables were compared using the chi-square test. A logistic regression analysis was performed to determine the association between the US findings and the DMSA scans in the presence of VUR. The sensitivity, specificity, positive predictive value, and negative predictive value (NPV) of US and late DMSA findings for VUR were calculated. A p-value <0.05 was considered significant.

Results

Demographic and Imaging Features of the Study Group

The records of 317 patients with a first febrile UTI were retrospectively reviewed in this study. The data of 97 patients who failed to meet the inclusion criteria were excluded from the study. The findings of the DMSA scan, renal US, and MCUG of the remaining 220 patients were analyzed. Figure 1 shows the flow of participant selection. The mean follow-up time was 3.9 ± 1.37 years (range 2.54-5.27 years). The mean age of the patients was 4.3 ± 2.07 years old (range 2-6.5 years). Of the 220 children, the female/male ratio was 1.53:1 (133 girls and 87 boys).

Abnormal US was determined in 130 patients. Hydronephrosis was the most common finding (n=86).

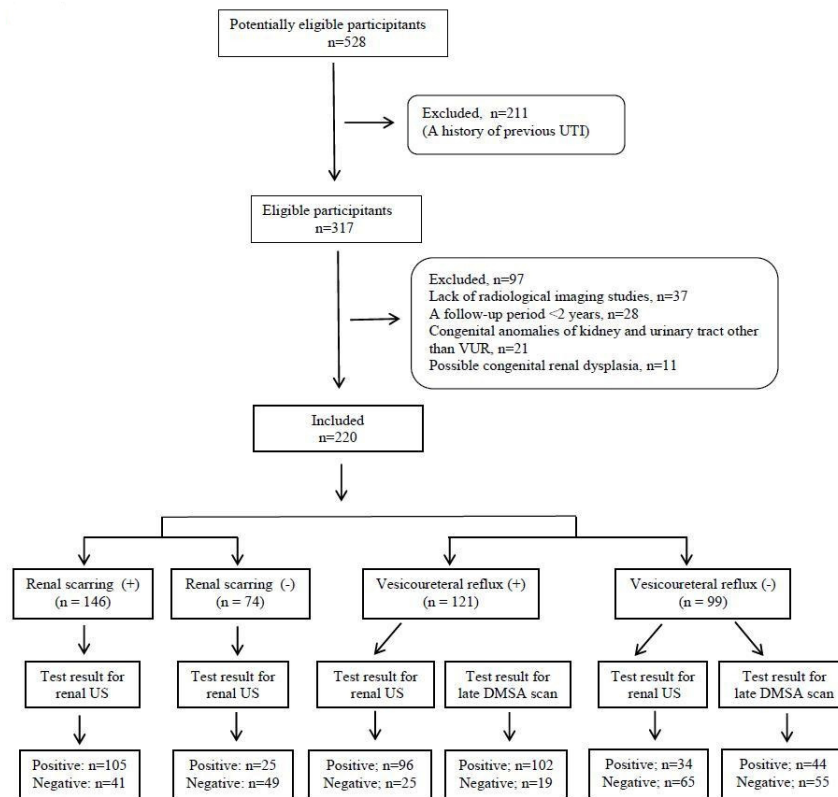


Figure 1. Participant selection diagram

VUR: Vesicoureteral reflux, UTI: Urinary tract infection, DMSA: Dimercaptosuccinic acid, US: Ultrasonography

Other US findings were as follows: hydroureter (n=69), caliectasis (n=60), and parenchymal thinning (n=58). In 121 of the 220 patients, VUR was determined (61 patients showed mild VUR, and 60 showed severe VUR).

The Relationship Between Late DMSA Scan and Renal US

Renal scarring was determined in 146 patients (44 had mild scarring, 79 had moderate scarring, and 23 had severe scarring). The frequency of abnormal US was higher in those patients with scarring than those without scarring (n=105 and n=25, respectively; p=0.011).

Parenchymal thinning was shown in 58 patients, all of them with renal scarring. The frequency of hydronephrosis was higher in those patients with renal scarring than in those without renal scarring (n=68 and n=18, respectively; p=0.026). The frequency of parenchymal thinning was higher in those patients with severe scarring than in those patients with mild and moderate scarring (n=15, n=16, and n=27, respectively; p=0.013).

The Renal Ultrasound and Late DMSA Scan Findings of the Patients with VUR

The frequency of abnormal US was higher in those patients with VUR than in those without VUR (p=0.009). Those patients with VUR had higher frequencies of parenchymal thinning, hydronephrosis, and hydroureter (p=0.000, p=0.022, p=0.000, respectively; Table I). Those patients with severe VUR had higher frequencies of both hydronephrosis and parenchymal thinning than those patients with mild VUR (p=0.022 and p=0.000, respectively; Table II). Twenty five (20.7%) patients with VUR (14 with mild VUR, and 11 with severe VUR) had normal renal US.

Both moderate and severe scarring were common in the presence of VUR (p=0.000 for both of them). Those patients with VUR had a higher frequency of RDF when compared to those patients without VUR (p=0.000; Table I). A significant difference was not determined between those patients with mild and severe VUR in terms of the degree of renal scarring and RDF (detailed results are shown in Table II).

Table I. The features of the patients with and without vesicoureteral reflux

	Vesicoureteral reflux (+) n (%)	Vesicoureteral reflux (-) n (%)	p-value
Gender (female)	76 (62.8)	57 (57.6)	0.758
Abnormal US	96 (79.3)	34 (34.3)	0.009
Hydronephrosis	66 (54.5)	20 (20.2)	0.043
Caliectasis	38 (31.4)	22 (22.2)	0.139
Parenchymal thinning	48 (39.7)	10 (10.1)	0.001
Hydroureter	61 (50.4)	8 (8.1)	0.000
Renal scarring	102 (84.3)	44 (44.4)	0.001
Severe scarring	18 (14.9)	5 (5.1)	0.000
Moderate scarring	61 (50.4)	18 (18.2)	0.000
Mild scarring	23 (19)	21 (21.2)	0.956
Reduced differential function	96 (79.3)	13 (13.1)	0.000

Values were expressed as number and proportion.
A p-value <0.05 was considered significant
US: Ultrasonography

Table II. The features of the patients with mild and severe vesicoureteral reflux

	Mild vesicoureteral reflux (+) n (%)	Severe vesicoureteral reflux (+) n (%)	p-value
Gender (female)	36 (59)	40 (66.7)	0.125
Abnormal US	47 (77.04)	49 (81.7)	0.392
Hydronephrosis	22 (36.1)	44 (73.3)	0.022
Caliectasis	17 (27.9)	21 (35)	0.857
Parenchymal thinning	8 (13.2)	40 (66.7)	0.000
Hydroureter	17 (27.9)	44 (73.3)	0.029
Renal scarring	47 (77.04)	55 (91.7)	0.046
Severe scarring	9 (14.8)	9 (15)	0.911
Moderate scarring	29 (47.5)	32 (53.3)	0.548
Mild scarring	9 (14.8)	14 (23.3)	0.106
Reduced differential function	44 (72.1)	52 (86.7)	0.094

Values were expressed as number and proportion.
A p-value <0.05 was considered significant
US: Ultrasonography

The Relationships Between Renal US, Late DMSA Scan, and the Presence/Grade of VUR

A logistic regression analysis showed a significant association between abnormal US and VUR or severe VUR (p=0.019 and p=0.011, respectively). Parenchymal thinning was associated with both VUR and severe VUR (p=0.038 and p=0.010, respectively). Renal scarring had a predictive value for VUR (p=0.005). While severe and moderate scarring were associated with the presence of VUR, there was no significant relationship between severe VUR and the degree of renal scarring. There was a significant association between RDF and VUR but not severe VUR (p=0.015 and p=0.242, respectively). Detailed results of the logistic regression analysis are shown in Table III.

The true and false positive/negative values and diagnostic accuracy of late DMSA scan and US to detect VUR and severe VUR are shown in Tables IV and V. Abnormal ultrasound had a sensitivity of 79.34% for VUR and 81.67% for severe VUR. The specificity of abnormal ultrasound was 65.66% for VUR and 70.63% for severe VUR. The NPV of abnormal US was 91.13% for severe VUR. Renal scarring on late DMSA scan had a sensitivity of 84.3% for VUR and 91.67% for severe VUR. The NPV of renal scarring was 73.68% for severe VUR.

Discussion

The results of our study showed that parenchymal thinning and hydroureter were significant indicators for both the presence and degree of VUR in older children who had their first FUTI. There was a significant association between the presence of VUR and renal scarring and RDF on late DMSA scan. However, no relationship was found between the degree of renal scarring and different grades of VUR.

VUR is considered to be one of the most common urological anomalies that can predispose children to UTI. The incidence of VUR varies between 0.5% and 3% in healthy children, but the frequency of VUR rises to 30-64% in children with UTI (7,8). In our study, VUR was detected in 55% of patients who had their first FUTI. This result supports the need for more determining indicators to perform MCUG in children during their first FUTI so as to not miss a diagnosis of VUR.

An acute-phase DMSA scan has an important role in detecting parenchymal infection during active infection. Previous studies have shown that while the frequency of abnormal DMSA scan ranged from 51% to 73% during the acute period of FUTI, the frequency of permanent scarring

Table III. Logistic regression analysis showing factors associated with presence of vesicoureteral reflux and severe vesicoureteral reflux

	Vesicoureteral reflux			Severe vesicoureteral reflux		
	OR	95% CI	p-value	OR	95% CI	p-value
Female gender	0.869	0.217-1,036	0.981	0.346	0.017-0.936	0.851
Abnormal US	1,549	1,215-5,541	0.019	1,417	1,153-6,439	0.011
Hydronephrosis	0.816	0.882-5,799	0.089	1,828	1,212-31,937	0.028
Caliectasis	0.522	0.575-4,936	0.341	0.191	0.156-2,650	0.459
Parenchymal thinning	1,130	1,058-7,415	0.038	2,175	1,692-45,761	0.010
Hydroureter	2,350	1,265-6,796	0.014	3,689	1,551-5,271	0.003
Renal scarring	2,317	1,624-9,174	0.005	1,216	1,108-1,471	0.043
Severe scarring	1,416	1,216-4,480	0.038	0.362	0.218-1,019	0.837
Moderate scarring	1,248	1,116-2,635	0.041	0.503	0.259-0.925	0.757
Mild scarring	0.415	0.172-1,109	0.691	0.215	0.127-0.815	0.947
Reduced differential function	1,420	1,324-12,936	0.015	0.386	0.025-2,550	0.242

A p-value <0.05 was considered significant
OR: Odds ratio, CI: Confidential interval, US: Ultrasonography

Table IV. The true and false positive/negative values for late DMSA scan and ultrasound to detect VUR and severe VUR

Test result	VUR (+)	VUR (-)	Severe VUR (+)	Mild VUR
Renal scarring	102	44	55	47
Positive	19	55	5	14
Negative	121	99	60	61
Abnormal renal ultrasound	96	34	49	47
Positive	25	65	11	14
Negative	121	99	60	61

VUR: Vesicoureteral reflux, DMSA: Dimercaptosuccinic acid

on the late DMSA scan was only 9.5%-11.9% (9,10). Studies have also reported a higher prevalence of permanent renal damage after acute pyelonephritis (11). Orellana et al. (12) showed that children older than one year had a higher frequency of renal scarring than infants. The frequency of permanent renal scarring was quite high (66.4%) in our patients who had their first FUT. The high frequency of renal scarring might be due to the fact that we included older children in our study. In addition, differences such as type of imaging study, age at diagnosis, clinical presentation, and the distribution of the severity of VUR could affect the prevalence of renal scarring.

There is little consensus and little data on imaging after FUT in older children (13). Hitzel et al. (14) suggest that MCUG is not necessary in children who have a normal US and DMSA scan. The revised guidelines by the Indian Pediatric Nephrology Group recommend DMSA scan as the

Table V. Diagnostic accuracy of renal bladder ultrasound and late DMSA scan to detect vesicoureteral reflux and severe vesicoureteral reflux

	Vesicoureteral reflux	Severe vesicoureteral reflux
Abnormal ultrasound		
Sensitivity (%)	79.34 (71.03-86.16)	81.67 (69.56-90.48)
Specificity (%)	65.66 (55.44-74.91)	70.63 (62.92-77.55)
+ Predictive value (%)	73.85 (67.94-79)	51.04 (44.35-57.69)
- Predictive value (%)	72.22 (64.07-79.13)	91.13 (85.65-94.65)
Renal scarring on late DMSA scan		
Sensitivity (%)	84.3 (76.57-90.27)	91.67 (81.61-97.24)
Specificity (%)	55.56 (45.22-65.55)	22.95 (13.15-35.53)
+ Predictive value (%)	69.86 (64.74-74.54)	53.92 (50.01-57.79)
- Predictive value (%)	74.32 (64.89-81.93)	73.68 (51.82-87.94)

DMSA: Dimercaptosuccinic acid

first approach (followed by VCUG if positive) in children between the ages of one and five years after their first UTI (15). Doğan et al. (16) found that abnormal DMSA scan findings had a sensitivity of 83.87% for VUR in 32 children older than two years with recurrent UTI. However, their study included patients with urological abnormalities other than VUR, as well as children with bladder and/or bowel dysfunction (16). Balestracci et al. (17) investigated the predictive role of late DMSA scan for high-grade VUR in 122 children aged between 3 and 18 years with FUT. They also included patients with FUT which occurred before the

first year of life. Of their patients, 57.4% had an abnormal late DMSA scan. Abnormal late DMSA scan was associated with both VUR and high-grade VUR (17). We determined a sensitivity of 84.3% of the abnormal late DMSA scan for the presence of VUR. Our study included DMSA scan findings of patients with their first FUTl. We did not include patients with urological abnormalities other than VUR, or patients with bladder and/or bowel dysfunction or a history of FUTl before the study. Our results showed that abnormal late DMSA scan could predict the presence of VUR in older children who had their first FUTl.

Researchers have drawn different conclusions about the relationship between abnormal DMSA scan and severe VUR. Silva et al. (18) reported that severe VUR was associated with all subtypes of renal damage. In their study, the median age at diagnosis of the first UTI was 8.9 months, and the median age at diagnosis of VUR was 19 months. Interestingly, Jang et al. (19) showed that abnormal DMSA scan was more common in the presence of severe VUR in patients less than 1 year old. However, they could not show the same relationship in patients over 1 year old (19). Lee et al. (20) did not find a significant difference in the prevalence of renal scarring between the different grades of VUR in children between 0 and 5 years of age. In our study, late DMSA scan had a sensitivity of 91.67% for severe VUR. However, we did not identify a significant association between severe VUR and the degree of renal scarring.

The literature contains conflicting conclusions about the predictive value of renal US for VUR. Several studies found no significant association between US findings and the presence of VUR (21). Conversely, Darge (22) reported that cortical thinning, small kidneys, and cortical hyperechogenicity were associated with the presence of VUR. Doğan et al. (16) reported that renal US had a sensitivity of 75% for the presence of VUR. In the study by Balestracci et al. (17) of the 69 patients with normal renal US, 32 (46.3%) had VUR. In our study, abnormal US had a sensitivity of 79.34% for VUR; nevertheless, one-fifth of our patients with VUR had no abnormal US findings. Our results indicated that older children who had their first FUTl could have VUR even if renal US is normal.

There are also different opinions concerning the ability of US to detect the grade of VUR. Bayram et al. (23) reported that the frequency of abnormal US was higher in patients with grades 4-5 of VUR (18). Another study showed renal US had a sensitivity of 63%-86% in the diagnosis of severe VUR (19,24). Our results revealed that the sensitivity of abnormal renal US was 81.67%, and NPV was 91.13% for severe VUR. Based on the results of our study, normal renal US could

indicate the absence of severe VUR in older children who have their first FUTl.

VUR is thought to be the most important risk factor for the development of renal scarring. However, recently, it has been suggested that UTI is more closely related to the development of permanent scarring than VUR (25). In our study, 44 patients had scarring but did not have VUR. This result might indicate that factors other than VUR, such as the severity of the inflammatory reaction, differences in the immunological system, and microbiological virulence factors, could play a role in the development of renal scarring.

Although renal US provides information about anatomic disorders of the kidney and urinary tract, several studies have shown that US is not a good determinant of renal scarring after the first UTI. Bush et al. (26) demonstrated that about one-fifth of children diagnosed with FUTl had renal scarring despite normal renal US. The false negative rate of renal US was 23% in children aged two years and older (21). Inversely, Merguerian et al. (27) found a significant correlation between renal US findings and diffuse renal scar, although there was a weak correlation between focal scar and renal US (22). In our study, about a third of patients with renal scarring had normal renal US. Accordingly, normal renal US cannot exclude the presence of renal scarring on late DMSA scan.

Study Limitations

This study has several limitations. First, this is a retrospective study with a small sample size. Second, our study could not distinguish whether DMSA scan abnormalities were congenital or acquired in patients without VUR. DMSA defects in these patients might be caused by congenital dysplasia, rather than UTI or VUR. Third, the reason for the high frequency of renal scarring might be related to possible previously undiagnosed infections. However, since this study was based on recorded medical data, we could not ascertain whether the symptoms of UTI had been present previously.

Conclusion

Our results showed that late DMSA scan findings were able predict the presence and grade of VUR in older children who had their first FUTl, and normal renal US was able predict the absence of severe VUR. However, older children who had their first FUTl should be investigated in terms of VUR after acute infection, even if renal scarring and abnormal renal US is not detected.

Ethics

Ethics Committee Approval: The protocol for the present study was reviewed and approved by the Institutional Review Board of Eskişehir Osmangazi University Faculty of Medicine (approval number: 25403353-050.99-E.110593).

Informed Consent: Retrospective study.

Peer-review: Externally peer-reviewed.

Authorship Contributions

Concept: N.Ç., Design: N.Ç., A.K.T., Data Collection or Processing: N.Ç., Analysis or Interpretation: N.Ç., İ.A.S., N.A., Writing: N.Ç., A.K.T., İ.A.S., N.A.

Conflict of Interest: No conflict of interest was declared by the authors.

Financial Disclosure: The authors declared that this study received no financial support.

References

1. Shaikh N, Morone NE, Bost JE, Farrell MH. Prevalence of urinary tract infection in childhood: a meta-analysis. *Pediatr Infect Dis J* 2008; 27:302-8.
2. Downs SM. Technical report: urinary tract infections in febrile infants and young children. *Pediatrics* 1999; 103:e54. doi: 10.1542/peds.103.4.e54.
3. Mori R, Lakhanpaul M, Verrier-Jones K. Diagnosis and management of urinary tract infection in children: summary of NICE guidance. *BMJ* 2007; 335:395-7.
4. Riccabona M, Avni FE, Blickman JG, et al. Imaging recommendations in paediatric urology: minutes of the ESPR workgroup session on urinary tract infection, fetal hydronephrosis, urinary tract ultrasonography and voiding cystourethrography, Barcelona, Spain, June 2007. *Pediatr Radiol* 2008; 38:138-45.
5. Nguyen HT, Herndon CD, Cooper C, et al. The Society for Fetal Urology consensus statement on the evaluation and management of antenatal hydronephrosis. *J Pediatr Urol* 2010; 6:212-31.
6. Polito C, La Manna A, Rambaldi PF, Nappi B, Mansi L, Di Toro R. High incidence of a generally small kidney and primary vesicoureteral reflux. *J Urol* 2000; 164:479-82.
7. MacKenzie JR, Fowler K, Hollman AS, et al. The value of ultrasound in the child with an acute urinary tract infection. *Br J Urol* 1994; 74:240-4.
8. Herz D, Merguerian P, McQuiston L, et al. 5-year prospective results of dimercapto-succinic acid imaging in children with febrile urinary tract infection: proof that the top-down approach works. *J Urol* 2010; 184(Suppl 4):1703-9.
9. RIVUR Trial Investigators, Hoberman A, Greenfield SP, et al. Antimicrobial prophylaxis for children with vesicoureteral reflux. *N Engl J Med* 2014; 370:2367-76.
10. Shaikh N, Mattoo TK, Keren R, et al. Early antibiotic treatment for pediatric febrile urinary tract infection and renal scarring. *JAMA Pediatr* 2016; 170:848-54.
11. Lin KY, Chiu NT, Chen MJ, et al. Acute pyelonephritis and sequelae of renal scar in pediatric first febrile urinary tract infection. *Pediatr Nephrol* 2003; 18:362-5.
12. Orellana P, Baquedano P, Rangarajan V, et al. Relationship between acute pyelonephritis, renal scarring, and vesicoureteral reflux. Results of a coordinated research project. *Pediatr Nephrol* 2004; 19:1122-6.
13. Kurtz MP, Chow JS, Johnson EK, Rosoklija I, Logvinenko T, Nelson CP. Imaging after urinary tract infection in older children and adolescents. *J Urol* 2015; 193(Suppl 5):1778-82.
14. Hitzel A, Liard A, Véra P, Manrique A, Ménard JF, Dacher JN. Color and power Doppler sonography versus DMSA scintigraphy in acute pyelonephritis and in prediction of renal scarring. *J Nucl Med* 2002; 43:27-32.
15. Indian Society of Pediatric Nephrology, Vijayakumar M, Kanitkar M, Nammalwar BR, Bagga A. Revised statement on management of urinary tract infections. *Indian Pediatr* 2011; 48:709-17.
16. Doğan ÇS, Koyun NS, Aksoy GK, Çekiç B, Savaş M, Çomak E. Delayed diagnosis of primary vesicoureteral reflux in children with recurrent urinary tract infections: diagnostic approach and renal outcomes. *Turk J Urol* 2018; 44:498-502.
17. Balestracci A, Montecucio M, Serviddio C, et al. Role of late DMSA renal scan in detecting high-grade vesicoureteral reflux. *Indian J Pediatr* 2019; 86:784-9.
18. Silva JM, Diniz JS, Lima EM, et al. Independent risk factors for renal damage in a series of primary vesicoureteral reflux: a multivariate analysis. *Nephrology (Carlton)* 2009; 14:198-204.
19. Jang HC, Lee KH, Park JS. Primary vesico-ureteral reflux: comparison of factors between infants and children. *Korean J Urol* 2011; 52:206-9.
20. Lee JH, Son CH, Lee MS, Park YS. Vesicoureteral reflux increases the risk of renal scars: a study of unilateral reflux. *Pediatr Nephrol* 2006; 21:1281-4.
21. Montini G, Zucchetta P, Tomasi L, et al. Value of imaging studies after a first febrile urinary tract infection in young children: data from Italian renal infection study 1. *Pediatrics* 2009; 123:e239-46. doi: 10.1542/peds.2008-1003
22. Darge K. Diagnosis of vesicoureteral reflux with ultrasonography. *Pediatr Nephrol* 2002; 17:52-60.
23. Bayram MT, Kavukcu S, Alaygut D, Soylu A, Cakmakci H. Place of ultrasonography in predicting vesicoureteral reflux in patients with mild renal scarring. *Urology* 2014; 83:904-8.
24. Tsai JD, Huang CT, Lin PY, et al. Screening high-grade vesicoureteral reflux in young infants with a febrile urinary tract infection. *Pediatr Nephrol* 2012; 27:955-63.
25. Prasad MM, Cheng EY. Radiographic evaluation of children with febrile urinary tract infection: bottom-up, top-down, or none of the above? *Adv Urol* 2012; 716-39.
26. Bush NC, Keays M, Adams C, et al. Renal damage detected by DMSA, despite normal renal ultrasound, in children with febrile UTI. *J Pediatr Urol* 2015; 11:126.e1-7.
27. Merguerian PA, Jamal MA, Agarwal SK, et al. Utility of SPECT DMSA renal scanning in the evaluation of children with primary vesicoureteral reflux. *Urology* 1999; 53:1024-8.