



Nasal Actinomyces in a 7-year-old Boy with Recurrent Nasal Bleeding: A Case Report

© Mohammad Solduzian¹, © Abbasali Hosseinpourfeizi², © Amir Hossein Jafari-Rouhi³, © Fariba Pourkarim¹

¹Tabriz University of Medical Sciences Faculty of Pharmacy, Department of Clinical Pharmacy, Tabriz, Iran

²Tabriz University of Medical Sciences, Hematology Oncology Research Center, Tabriz, Iran

³Tabriz University of Medical Sciences, Tuberculosis and Lung Diseases Research Center, Tabriz Iran

ABSTRACT

Actinomyces rarely cause infections in nasal sinuses with local symptoms and its identification is difficult so the initiation of treatment might be delayed. A 7-year-old boy with recurrent nasal bleeding was found to be infected in the paranasal sinuses with actinomyces, which was confirmed by histopathological studies. This case was initially managed with surgical resection and systemic antibiotics and later discharged and referred to an out-patient clinic.

Keywords: Actinomyces, nasal sinus, recurrent bleeding

Introduction

The actinomyces species, fastidious gram-positive anaerobic bacteria, have been identified as an uncommon cause of infection in humans. These organisms remain in the host mucosa and invade the lower layers after the breakdown of protective barriers (1). They might consist of normal flora of the pharynx, but organisms might spread to the paranasal sinuses and other cervicofacial regions and cause infections in the gastrointestinal tract, thorax, head, and neck, or less commonly in female genitalia, the ophthalmic region and the oral cavity. Isolation of these organisms is difficult and histologic studies are required for their identification (2). The clinical presentation of actinomycosis might resemble malignancy and imaging studies are necessary for differentiation. Poor dental hygiene is the most frequently reported risk factor for cervicofacial

actinomyces infection. Chronic gingivitis, dental procedures and other chronic disorders of the oral cavity could also increase the risk of cervicofacial actinomyces infection (3). A cervicofacial infection of actinomyces can lead to abscess formation, osteomyelitis or osteonecrosis. In cases of cervicofacial infection, treatment usually consists of surgical interventions for the drainage of abscesses and the debridement of necrotic bone tissue, in combination with prolonged courses of antibiotics (usually 6 to 12 months). Antibiotic options include amoxicillin, ceftriaxone, penicillin, clindamycin, macrolides and doxycycline. Some studies have reported successful treatment of cervicofacial actinomyces with 4 to 6 week courses of antibiotic therapy which is shorter compared to previously recommended durations (4). Actinomyces infections are rare and the incidence rate of these infections is 1 case in 300,000 (5). Pediatric actinomyces infections are rare and early

Address for Correspondence

Mohammad Solduzian, Tabriz University of Medical Sciences Faculty of Pharmacy, Department of Clinical Pharmacy, Tabriz, Iran
Phone: +989120920355 E-mail: dr.mohammadsolduzian@gmail.com ORCID: orcid.org/0000-0002-7504-5065

Received: 16.06.2021 **Accepted:** 11.08.2021

©Copyright 2022 by Ege University Faculty of Medicine, Department of Pediatrics and Ege Children's Foundation
The Journal of Pediatric Research, published by Galenos Publishing House.

epidemiological data indicate that it might account for less than 3% of all actinomyces infections (6). Some patterns of infection are even rarer such as nasal cavity involvement. In the current paper, we report a case of nasal cavity involvement with actinomyces, proven in histologic studies, who was managed with surgical debridement and intravenous antibiotics.

Case Presentation

A 7-year-old boy with poor oral hygiene was admitted to the emergency department of Tabriz Children's Hospital, a teaching hospital of Tabriz University of Medical Sciences, for the management of epistaxis. His medical history showed recurrent epistaxis during the previous three months leading to frequent emergency visits. He had previously undergone two nasal cautery for the treatment of epistaxis. The child was conscious but appeared pale. His vital signs were as follows; BP of 90/50 mmHg; body temperature of 37.5 °C; a pulse of 141 beats/minute; and a respiratory rate of 31 breaths/minute. On auscultation, his heart sounds were normal and his lungs were clear. Blood tests showed a high white blood cell count (lymphocyte predominance), and anemia (hemoglobin=8.1 g/dL). Other parameters including creatinine, platelet count, prothrombin time, partial thromboplastin time, and international normalized ratio were within the normal range (Table I). His erythrocyte sedimentation rate was 10 mm/hour (reference value: up to 12), while C-reactive protein was negative. A nasal tampon was inserted into the anterior of the nose. Active bleeding from the nose was stopped but the patient occasionally had bloody discharge from the pharynx. Other treatments included 800 mL of 10% dextrose solution intravenously, a transfusion of 350 mL fresh frozen plasma, a transfusion of

2 units of packed red blood cells, tranexamic acid (400 mg slow intravenous infusion 2 times daily), furosemide (15 mg intravenously), 3 drops of phenylephrine into each nostril every 8 hours, and 5 mL of syrup zinc sulfate orally per day.

Computed tomography (CT) angiography of the neck vessels showed opacities in the paranasal sinuses. No evidence of space occupying mass, obvious vascular lesions, stenosis or blockage in the carotid artery or obvious vascular leakage in the nasopharynx or its surrounding spaces was observed.

A CT scan of the brain with radiocontrast media revealed mucosal thickening in the left maxillary sinus, suggesting a retention cyst or polyp measuring 17×15 mm. The nasal cuts can be seen in Figure 1. Osteomeatal complex obstruction and a mass in the nasal cavities was also identified. There

Parameter	On admission	At discharge
WBC ($\times 10^3/\text{mm}^3$)	14.69	14.3
Lymphocytes ($\times 10^3/\text{mm}^3$)	4.19	6.4
Neutrophils ($\times 10^3/\text{mm}^3$)	4.97	6.9
Hemoglobin (g/dL)	8.1	11.6
Platelet count ($\times 10^3/\text{mm}^3$)	297	233
Creatinine (mg/dL)	0.5	0.4
PT (sec)	12.4	12
PTT (sec)	42	24
INR (sec)	1	1

WBC: White blood cells, PT: Prothrombin time, PTT: Partial thromboplastin time, INR: International normalized ratio

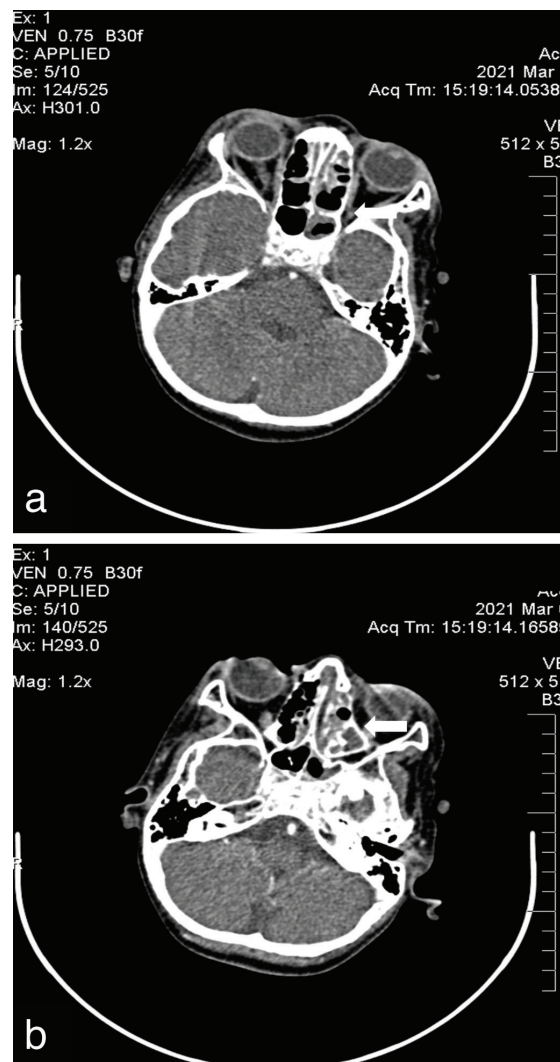


Figure 1. Brain computed tomography of the patient. Sinus involvement was noted

was no evidence of any brain space occupying mass in the brain parenchyma. There was no evidence of any nasopharyngeal mass or juvenile angiofibroma.

Surgical nasoscopy was performed to avoid bleeding. Following this, a specimen from the nasopharynx lesion was put into a fixative solution (formalin). The gross examination consisted of one dark-gray-colored tissue. One fragment of tube like tissue measuring 7.5×1.2 cm and another with a smooth surface measuring 5×2 cm was obtained for histopathology study. Histopathological investigation of the resected mass revealed actinomycotic colonies with fibrin leukocyte deposition and focal lymphoid aggregation.

Following the pathology report, the patient was initially treated with 500 mg of intravenous ceftriaxone every 12 hours for 6 days. After stabilization and control of the fever and bleeding, he was discharged and referred to an ear, nose and throat clinic for prolonged antibiotic therapy and follow-up.

Discussion

Overall, the number of cases with proven post nasal actinomyces is limited. The masses that are formed in patients with sinus actinomyces infection might look like malignant disease at first and require confirmatory work-up. The indolent nature of the organism can lead to a prolonged duration of the disease and several antibiotic trials. The masses that are formed in this type of involvement may be expansive and have bony erosions. Also, they might mimic fungal infections. The diagnosis of actinomyces should always be kept in mind when the patient has poor dental hygiene, which raises the suspicion of this infection (7).

As has been described in some cases, nasal actinomyces might present with a prolonged change in smell and purulent nasal discharge in patients without a known baseline medical condition. Also, it has been reported that nasal actinomyces can affect patients without any remarkable laboratory findings or lymphadenopathy and might look like a foreign body, although it may share radiological findings with fungal infections as well (8).

Although nasal actinomyces can be successfully managed with surgical resection and prolonged antibiotic therapy, death has also been reported following this infection. In a middle aged man with unilateral nasal obstruction, edema and pain, who had history of diabetes mellitus and hepatitis C, poor compliance with the antibiotic regimen and follow-up resulted in necrosis expansion, disseminated intravascular coagulation, multiple end organ failure and death (9).

That case highlights the importance of surgical intervention and the proper selection of the antibiotic regimen. The deceased patient did not undergo surgical debridement at first and this intervention was only performed following the dissemination of the infection and the rise of inflammatory markers. In addition, antibiotics were not given in a comprehensive way, with multiple discontinuation and adjustments.

In our case, the patient underwent surgical debridement and ceftriaxone was started and continued until discharge, at which point, the patient was referred to an out-patient clinic for further follow-up.

Dental procedures can result in an exposure to actinomyces embedded in the nasal cavity. One case described nasal actinomyces that were found following a tooth extraction which resulted in discharge and odor from the extraction site. Following these initial signs and symptoms and maxillary tenderness, the patient was evaluated with nasal endoscopy and surgical debridement followed by a prolonged course of oral antibiotics (10).

Considering that the sinus cavity is anatomically related to multiple sites and actinomyces could actually spread to it from junctional sites, it might be reasonable to rule out actinomyces infection in patients with extended signs and symptoms of sinusitis and no response to proper antibiotics. In our case, poor dental hygiene was noticeable and this may have contributed to nasal involvement.

Nasal sinus actinomyces infection may be observed following other infections that impair oxygenation of the area, such as nasal mucormycosis. In such cases, it might be difficult to distinguish between recurrent infections and new involvement with actinomyces, and so, pathologic evaluations should be done carefully as misdiagnosis can change the course of the therapy (11).

The patient presented in our case had several interesting features. All the cases discussed above were above middle age, while our patient was a 7-year-old boy. Also, all other cases had some type of risk factor which predisposed them to actinomycosis, while at the time of discharge, no confirmed immunologic or metabolic disease had been recorded for our patient and the only predisposing factor was poor oral hygiene.

In conclusion, it is worth remembering that actinomyces may infect children as well as adults and this organism should be suspected in those patients with nasal abscess, bleeding and a mass detected in radiologic studies. The process of isolation and culture of the organism can be

difficult and strong suspicion is needed in order to carry out proper laboratory investigations.

Ethics

Informed Consent: All patients are asked to sign an informed consent note at the time of hospital admission for general care.

Peer-review: Externally and internally peer-reviewed.

Authorship Contributions

Concept: M.S., A.H., A.H.JR., F.P., Design: M.S., A.H., A.H.JR., F.P., Data Collection and/or Processing: M.S., A.H., A.H.JR., F.P., Analysis and/or Interpretation: M.S., A.H., A.H.JR., F.P., Literature Search: M.S., A.H., A.H.JR., F.P., Writing: M.S., A.H., A.H.JR., F.P.

Conflict of Interest: The authors declared that there were no conflicts of interest.

Financial Disclosure: The authors declared that this study has received no financial support.

References

1. Könönen E, Wade WG. Actinomyces and related organisms in human infections. *Clin Microbiol Rev* 2015; 28:419-42.
2. Hall V. Actinomyces--gathering evidence of human colonization and infection. *Anaerobe* 2008; 14:1-7.
3. Boyanova L, Kolarov R, Mateva L, Markovska R, Mitov I. Actinomycosis: a frequently forgotten disease. *Future Microbiol* 2015; 10:613-28.
4. Moghimi M, Salentijn E, Debets-Ossenkop Y, Karagozoglou KH, Forouzanfar T. Treatment of cervicofacial actinomycosis: a report of 19 cases and review of literature. *Med Oral Patol Oral Cir Bucal* 2013; 18:e627-32.
5. Acevedo F, Baudrand R, Letelier LM, Gaete P. Actinomycosis: a great pretender. Case reports of unusual presentations and a review of the literature. *Int J Infect Dis* 2008; 12:358-62.
6. Benammar S, H elardot PG, Sapin E, Adamsbaum C, Raymond J. Childhood actinomycosis: report of two cases. *Eur J Pediatr Surg* 1995; 5:180-3.
7. Saibene AM, Di Pasquale D, Pipolo C, Felisati G. Actinomycosis mimicking sinonasal malignant disease. *BMJ Case Rep* 2013; 2013:bcr2013200300.
8. Batzakakis D, Karkos PD, Papouliakos S, Leong SC, Bardanis I. Nasal actinomycosis mimicking a foreign body. *Ear Nose Throat J* 2013; 92:E14-6.
9. Sakuma Y, Yamashita Y, Shiono O, Oridate N. Actinomycosis arising from the nasal cavity, with rare fatal progression. *BMJ Case Rep* 2016; 2016:bcr2015213747.
10. Cohn JE, Lentner M, Li H, Nagorsky M. Unilateral Maxillary Sinus Actinomycosis with a Closed Oroantral Fistula. *Case Rep Otolaryngol* 2017; 2017:7568390.
11. Gupta V, Dwivedi G, Sengupta P, et al. A rare case of sinonasal actinomycosis - enigmatic presentation. *Int J Otorhinolaryngol Head Neck Surg* 2018; 4:863-7.